

Abstract

**Brusovtsov D.,
Lyndin M.,
Sikora V.,
Hyriavenko N.,
Romaniuk A.,**

*Sumy State University, Department
of Pathology, 31, Privokzalna st.,
Sumy, Ukraine*

**RESEARCH ON THE INCIDENCE OF MALIGNANT
TESTICULAR TUMORS IN UKRAINE AND SUMY REGION**

Oncological incidence of testicular cancer is the current medical and social problem in Ukraine and in the world. Despite the relatively low incidence rate for this pathology, it is of fundamental importance for clinicians, since it is the most common type of malignant tumors in young men of working age (15–45 years). In particular, the incidence of testicular cancer in Sumy region slightly differs from the national average. That is why the objective of our study was to analyze the level of testicular neoplasia among the population of Sumy region and Ukraine in 2011–2019, as well as to compare them. Based on the obtained data, Sumy region is included in the group of regions of Ukraine with an over-threshold incidence of testicular cancer. Statistical data analysis showed a tendency to a decrease of the overall incidence of testicular cancer among the adult population in Ukraine during the study period (on average, 2.55 per 100,000 population). At the same time, in Sumy region, there was a gradual increase in the frequency of cases of this oncopathology in men with the highest indicators reached in 2017 (4.33 per 100,000 population). Consequently, in Ukraine, this pathology affected men mainly at the age of 35–39. However, it is should be noted that the age range of morbidity in Sumy region was somewhat broader and mainly affected the population aged 30–39, and, in some years –men at the age of 20–29. It was established that testicular cancer affects the pediatric population, although it is extremely rare. Considering that seminoma is the most common type of testicular tumors, we focused on an in-depth study of its morphological features. Statistical data analysis revealed a link between the incidence of testicular cancer and the age of the male population. An important element of the research is the study of etiopathological factors that affect the growth of the degree of involvement, caused by this pathology.

Keywords: testicular cancer, incidence, oncopathology, statistics, seminoma.

Corresponding author: d.brusovtsov@gmail.com

Резюме**Брусовцов Д. О.,****Линдін М. С.,****Сікора В. В.,****Гирявенко Н. І.,****Романюк А. М.,***Сумський державний університет, кафедра патологічної анатомії, вул. Привокзальна 31, м. Суми, Україна. 40022***ДОСЛІДЖЕННЯ ЗАХВОРЮВАНОСТІ НА ЗЛОЯКІСНІ ПУХЛИНИ ЯЄЧКА В УКРАЇНІ ТА СУМСЬКІЙ ОБЛАСТІ**

Актуальною медико-соціальною проблемою України та в світі є онкологічна захворюваність на рак яєчка. Незважаючи на відносно невеликий рівень захворюваності на дану патологію, вона має принципове значення для клініцистів, так як це найпоширеніший тип злоякісних пухлин у молодих чоловіків працездатного віку (15–45 років). Зокрема, в Сумській області показник захворюваності на рак яєчка дещо відрізняється від середніх по країні. Саме тому, метою нашого дослідження стало проведення аналізу рівня неоплазій яєчка серед населення Сумщини та України в період 2011–2019 років, а також їх порівняння. Базуючись на отриманих даних, Сумська область входить до групи областей України з надпороговим рівнем захворюваності на рак яєчок. Аналіз статистичних даних показав тенденцію до зниження загального рівня захворюваності на рак яєчка серед дорослого населення в Україні у досліджуваний період (в середньому 2,55 на 100 тис. населення). У той же час, у Сумській області відмічалось поступове зростання частоти випадків даної онкопатології у чоловіків з досягненням найвищих показників у 2017 році (4,33 на 100 тис. населення). Відтак, по Україні на дану патологію хворіли чоловіки переважно у віці 35–39 років. Проте, варто відмітити, що віковий діапазон захворюваності в Сумській області був дещо ширшим та переважно вражав населення віком 30–39 років, а в деяких роках і чоловіків 20–29 років. Встановлено, що рак яєчка також вражає дитяче населення, хоча і зустрічається вкрай рідко. Враховуючи те, що найчастіше серед усіх пухлин яєчок зустрічається семінома, ми зупинились на більш детальному вивченні її морфологічних особливостей. В результаті аналізу статистичних даних виявлено зв'язок між захворюваністю на рак яєчка та віком чоловічої частини населення. Важливим елементом дослідження залишається вивчення етіопатологічних факторів, які впливають на зростання рівня ураження даною патологією.

Ключові слова: рак яєчка, захворюваність, онкопатологія, статистика, семінома.

Автор, відповідальний за листування: d.brusovtsov@gmail.com

Introduction

The death rate from malignant neoplasms is the second highest in the world after cardiovascular diseases. More than 18 million new cases are diagnosed each year, of which 9.5 million are fatal. Each year, these indicators steadily increase by about 3.0% [1, 2]. Among them, the number of newly diagnosed tumors of the sexual system in men is more than 2.3 million cases, including prostate cancer – 1.3 million, penile cancer – 34 thousand cases. It is known that in 2018, the indicator of testicular tumor ranked 27th in the structure of total cancer incidence and 21st in men – this is 71 thousand of new and 9.5 thousand of

fatal cases per year. Moreover, every year there is a tendency to an increase of these indicators [3, 4, 11].

Despite the relatively low incidence of testicular cancer, this pathology is of fundamental importance for clinicians, since it is the most common type of malignant tumors in young men of working age, which significantly affects their quality of life. In the world, the incidence of testicular cancer is 1.0 to 1.5% in the total structure of cancer incidence among men and 5.0% among all urogenital tract tumors [5]. Sumy region is included in the group of regions of Ukraine with an over-threshold level of malignant pathologies of various organs [9, 10], however the issue of coverage of statistical data

regarding the incidence of testicular cancer remains out of sight.

The frequency of testicular tumors depends on many factors: age (15–45 years), race, height (> 195 cm), environmental conditions, cryptorchidism, hydrocele, hormonal disorders, family history, atrophy, hypoplasia, and testicular dysgenesis, traumas, orchitis, etc [2,5]. Thus, most often testicular tumors are found in men of the European race (Scots, Americans, Canadians, Dutch), and much less often in representatives of the Negroid and Asian races [2, 6, 7]. There may be family cases, especially if it concerns siblings [5]. Often, it is the patient's age that correlates with the histological type of structure of a malignant testicular tumor (seminomas are more often diagnosed at the age of 25–45, non-seminal tumors are found in younger men aged 15–35 [6].

According to the histological structure, testicular tumors are germinogenic: seminomas (spermatogenic, aplastic), non-seminomic tumors (embryonic cancer, yolk-sac tumors, teratoblastoma, chorionepithelioma), and non-germinogenic tumors (gonadoblastoma, sertolioma, leydigoma). At the same time, 90–95% are germinogenic tumors. Therefore, it is the seminomas that have the greatest practical significance [2]. Histological diagnosis of these tumors is of fundamental importance in clinical practice, which affects the choice of treatment tactics and patient prognosis. A significant risk factor of the development of germinogenic testicular tumors is cryptorchidism. It is known that in case of the location of the testicles outside the scrotum, tumors develop 5 to 10 times more often. It is considered that the more pronounced the testicular dysgenesis syndrome, the greater the chance of testicular malignancy [2, 6].

An important etiopathogenetic factor is the side of testicular localization. Thus, according to international statistics, it is the right testicle that is affected more often. At the same time, bilateral lesion accounts for approximately 1–2 % of all cases [5, 7].

It is worth mentioning that the global death rate from testicular cancer is quite low. As of 2018, it was less than 1 per 100,000 population, which in absolute numbers is 9,507 deaths [2]. This is due to the ease of diagnosis, as well as the effectiveness of surgical and chemotherapeutic treatment. Due to

this, five-year survival of patients is 90–95% [2, 6]. The recovery prognosis in Eastern Europe is 10% less than in the Western part [8]. This is due to the low level of economic development indicators and, as a result, insufficient provision of hospital facilities with diagnostic systems and medications.

The disease prognosis depends on the histological type, stage of the disease, and men's age. Therefore, an important aspect is early and high-quality diagnosis, which includes a thorough clinical examination at the primary level of medical care and collection of anamnesis, especially for men in the second to fourth decade of life. In case of complaints or detection of anatomical abnormalities, it is recommended to conduct non-invasive and invasive examination methods, such as ultrasound, MRI, biopsies, measurement of the level of diagnostically important serum markers (alpha-fetoprotein, chorionic gonadotropin, lactate dehydrogenase and the alkaline phosphatase isoenzyme) [2,5,6,7].

Given the above, this topic remains very relevant and requires constant study. Therefore, the purpose of our research was a comparative analysis of statistical indicators of the incidence of testicular cancer in Ukraine and Sumy region in 2011–2019.

Materials and study methods

Based on the data of the Sumy Regional Clinical Oncological Dispensary, a screening analysis of the oncological incidence of testicular cancer among pediatric and adult population in Sumy region and Ukraine for the period 2011–2019 was conducted.

Study results and discussion

According to the analysis results, it was found that the highest incidence of testicular cancer in Ukraine among the adult population was in 2013 (3.11 per 100,000 population), the lowest – in 2017 (2.4 per 100,000 population). At the same time, the frequency of prevalence of this pathology in Sumy region differed from the all-Ukrainian indicators: the highest level in 2017 (4.33 per 100,000 population), and the lowest – in 2019 (1.96 per 100,000 population). Based on this, in contrast to the downward trend in the incidence of testicular cancer in Ukraine, there is a gradual increase in the incidence in Sumy region with the crossing (increase and decrease in incidence) in 2013–2014 (Fig. 1).

INCIDENCE OF TESTICULAR AMONG THE ADULT POPULATION

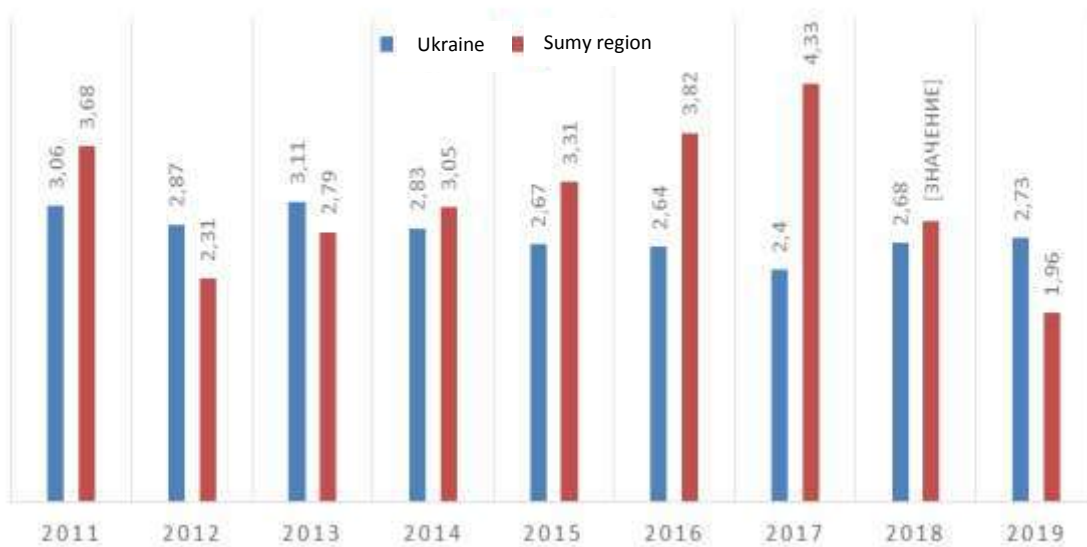


Figure 1 – Incidence of testicular cancer in Ukraine and Sumy region among the adult population in 2011–2019 (per 100,000 population)

Analysis of newly identified cases of this pathology in the adult population showed that the maximum number of cases of testicular cancer in Ukraine was 525 in 2013, and the minimum – in

2017 (377 cases). In contrast, in Sumy region, the largest number of patients with testicular cancer was detected in 2017 – 18 cases, and the lowest – in 2019 (8 cases) (Fig. 2).

NEWLY DIAGNOSED TESTICULAR CANCER CASES

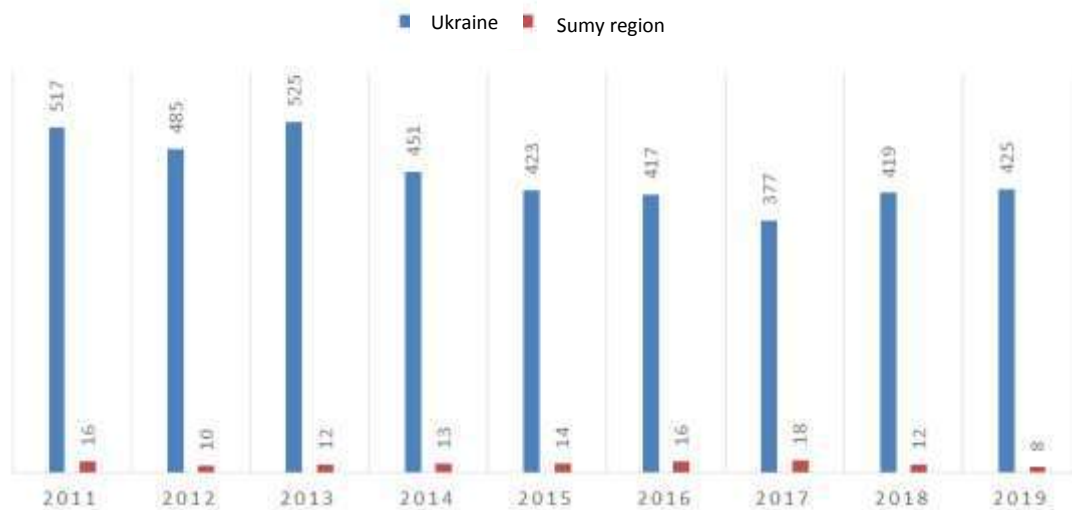


Figure 2 – Absolute number of patients with newly diagnosed testicular cancer in Ukraine and Sumy region among the adult population in 2011–2019

According to the results of a study of the incidence of testicular cancer in the population, there is a certain relationship with age. It was found that in general, in Ukraine, men aged 35–39

years (4.7 per 100,000 population) had this pathology, which coincided with the indicators in Sumy region (7.9 per 100,000 population). However, it is should be noted that the age range

of morbidity in the selected region was somewhat broader and mainly affected the population aged 30–39 years. However, as an exception, in 2017, testicular cancer was the most widespread among the working-age population of Sumy region at the age 20–24 years (9.9 per 100,000 population). In 2013, the incidence rate reached its peak (8.3 per 100,000 population) in patients aged 25–29 years.

It is important to note that the incidence of testicular cancer among pediatric (0–18 years) population throughout the country is quite low. The highest incidence of testicular cancer was

recorded in 2012 and 2014 – 18 and 19 cases (0.4–0.49 per 100,000 population), respectively, and the lowest – in 2011 – 4 cases (0.1 per 100,000 population). Such rates may indicate an increase in the number of new pediatric patients in recent years and a tendency to "juvenescence" of this oncological pathology. At the same time, in Sumy region, only one case of oncopathology in a child was registered in 2012 (1.08 per 100,000 population) and two cases in 2019 (2.3 per 100,000 population) (Fig. 3).

INCIDENCE AND ABSOLUTE NUMBER OF NEWLY DIAGNOSED TESTICULAR CANCER AMONG PEDIATRIC POPULATION

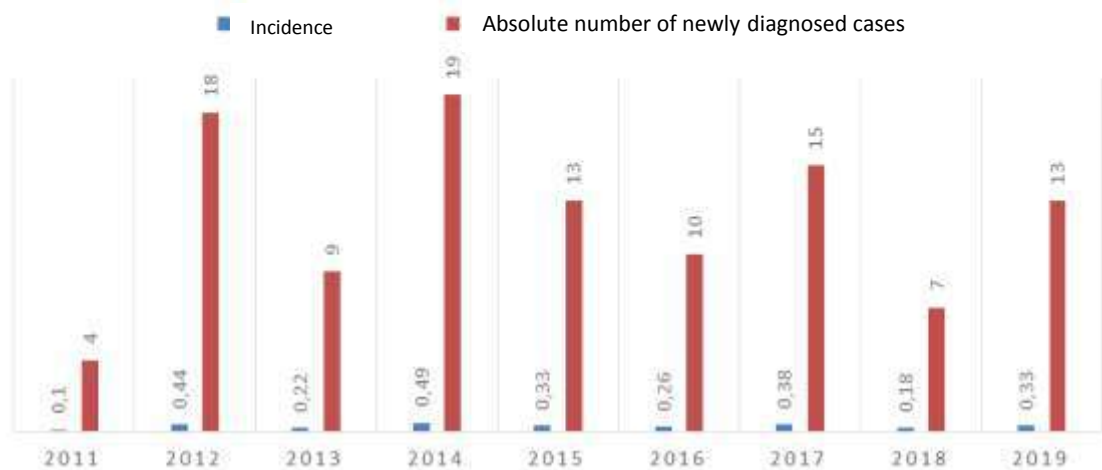


Figure 3 – The number of cases and incidence of testicular cancer in Ukraine among pediatric population in the period 2011–2019

Considering that seminoma is the most common type of testicular tumors, we focused on an in-depth study of its morphological features.

Macroscopically, the testicle is affected by the neoplastic process, is slightly enlarged in size and has a bumpy surface.

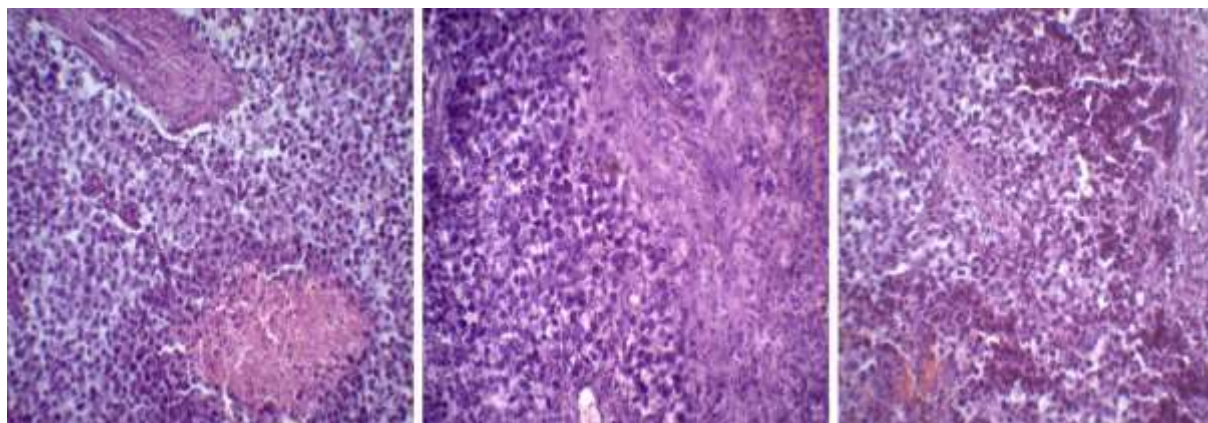


Figure 4 – Histological picture of seminoma. Staining: hematoxylin and eosin. Magnification: x200

Depending on the stage, some specimens showed the spread of the tumor to the epididymis and spermatic cord. On the section, nodes are grayish-pink in color, sometimes with foci of necrosis and hemorrhage. Microscopically, the tumor is represented by light cells with monomorphic rounded and oval nuclei with pathological mitoses. In the neoplasia tissue, there are palisade like structures, groups of glands, solid fields of tumor growth are separated by layers of connective tissue, microcysts, foci of necrosis and hemorrhage, as well as single gigantic mononuclear syncytiotrophoblast cells. Among the tumor microenvironment, there is a pronounced inflammatory lymphocytic infiltration, which is represented mainly by T-lymphocytes. In some histological specimens, the growth of the neoplasm

Conclusions

Statistical data analysis showed a tendency to decrease of the overall incidence of testicular cancer in Ukraine in the period 2011–2019. However, there was an increase in the incidences of this oncopathology in

Prospects for future research

The further research perspective is to conduct molecular and genetic studies of testicular cancer tissue with the establishment of the immunohistochemical profile of the tumor and its microenvironment.

Acknowledgements

This study is a part of the research project of the Department of Pathological Anatomy No.0119U100887 "Modern Views on Morphogenesis of General Pathological Processes", as well as a part of the state budget project No. 62.12.01-01.17/20.ZP "Development of a Method

into the testicular sheath, vascular invasion and spread to the spermatic cord is visualized.

Thus, the analysis of the incidence of testicular cancer in Ukraine and Sumy region showed some differences in the growth trends of this indicator in Sumy region. In our opinion, this situation can be explained by the deterioration of the environmental situation (pollution of the environment with the salts of heavy metals), and the peculiarities of diagnostics at different times in Sumy region. Activation of tumor growth and the mechanism of carcinogenesis in other organs of the reproductive system in a polluted environment are covered in our previous works [12, 13, 14]. A similar mechanism may occur in men with testicular cancer.

Sumy region. It was established that testicular cancer affects the pediatric population, although it is extremely rare. There is a link between the incidence of testicular cancer and the age of the male population.

Conflict of interest

The authors declare no conflict of interest.

Відомості про авторів

Брусовцов Дмитро Олегович, аспірант кафедри патологічної анатомії Сумського державного університету, м. Суми, Україна.

Електронна пошта: d.brusovtsov@gmail.com

ORCID: 0000-0003-2669-6774

Линдін Микола Сергійович, к.мед.н., доц. кафедри патологічної анатомії Сумського державного університету, м. Суми, Україна.

Електронна пошта: n.lyndin@med.sumdu.edu.ua

ORCID: 0000-0003-4385-3903

Сікора Владислав Володимирович, к.мед.н., асистент кафедри патологічної анатомії Сумського державного університету, м. Суми, Україна.

Електронна пошта: v.sikora@med.sumdu.edu.ua

ORCID: 0000-0002-4147-6879

for Diagnosis of Tumors of the Reproductive System Using Cancer-Embryonic Antigen Cell Adhesion Molecules" and No.62.14-01.18/20.ZP "Effectiveness of Liquid Biopsy and Tissue Biopsy in the Diagnosis and Treatment of Malignant Tumors".

Гирявенко Наталія Іванівна, к.мед.н., асистент кафедри патологічної анатомії Сумського державного університету, м. Суми, Україна.

Електронна пошта: n.guryavenko@med.sumdu.edu.ua

ORCID: 0000-0002-9805-014X

Романюк Анатолій Миколайович, д.мед.н., проф., завідувач кафедри патологічної анатомії Сумського державного університету, м. Суми, Україна.

Електронна пошта: pathomorph@gmail.com

ORCID: 0000-0003-2560-1382.

References (список літератури)

1. *International Agency for Research on Cancer*. Retrieved from: https://gco.iarc.fr/today/online-analysis-table?v=2018&mode=cancer&mode_population=continents&population=900&populations=900&key=asr&sex=0&cancer=39&type=0&statistic=5&prevalence=0&population_group=0&ages_group%5B%5D=0&ages_group%5B%5D=17&nb_items=5&group_cancer=1&include_nmsc=1&include_nmsc_other=1
2. Bondar HV, Dumans'kyi, YUV, Popovych OYU. *Onkolojiya* [Oncology]. Kyiv: Medytyna Publ, 2013. pp. 436-42.
3. Bray F, Ferley F, Soerjomataram I. Global cancer statistics 2018: GLOBOCAN estimates of incidence and mortality worldwide for 36 cancers in 185 countries. *CA Cancer J Clinicians*. 2018;68(6):394–424. doi: 10.3322/caac.21492
4. Siegel RL, Miller KD, Jemal A. *Cancer statistics, 2018*. *CA Cancer J Clin* 2018;68(1):7–30. Retrieved from: <https://www.ncbi.nlm.nih.gov/pubmed/29313949> doi: 10.3322/caac.21442
5. Albers P, Albrecht W, Algaba F, Bokemeyer C, Cohn-Cedermark G, Fizazi K, Horwich A, Laguna MP, Nicolai N, Oldenburg J; *European Association of Urology*. Guidelines on Testicular Cancer: 2015 Update. *Eur Urol*. 2015;68(6):1054-68. doi: 10.1016/j.eururo.2015.07.044 PMID: 26297604
6. Wild CP, Weiderpass E, Stewart BW. World cancer report: cancer research for cancer prevention. *International Agency for Research on Cancer*. 2020;430-8. Retrieved from: <https://shop.iarc.fr/products/world-cancer-report-cancer-research-for-cancer-prevention-pdf>
7. Kheffner L. *Polovaya sistema v norme i patologii* [The reproductive system is normal and in pathology]. Moskva: Geotar-Med Publ, 2013. pp.104-5.
8. Trama A, Foschi R, Larranaga N, Sant M, Fuentes-Raspall R, Serraino D. Survival of male genital cancers (prostate, testis and penis) in Europe 1999-2007: results from the EURO CARE-5 study. *Eur J Cancer*. 2015;51(15):206–16. Retrieved from: <https://www.ncbi.nlm.nih.gov/pubmed/26421823> doi: 10.1016/j.ejca.2015.07.027
9. Romanyuk AM, Sikora VV, Lyndin MS, Sikora VV, Piddubnyy AM. [Environmental factors resulting in urinary bladder pathology]. *Aktual'ni problemy suchasnoyi medytyny*. 2016;16(53):146-60.
10. Lyndin MS, Kravtsova OI, Karpenko LI, Panchenko VD, Romanyuk AM. [Epidemiology and morphology investigation of corpus uteri malignant tumors]. *Art of medicine*. 2018;3:66-71.
11. Park JS, Kim J, Elghiatty A, Ham WS. Recent global trends in testicular cancer incidence and mortality. *Medicine*. 2018;97(37):e12390. Retrieved from: <https://www.ncbi.nlm.nih.gov/pubmed/30213007> doi: 10.1097/MD.00000000000012390 PMID: 30213007
12. Romaniuk A, Lyndin M, Sikora V, Romaniuk S, Sikora K. Heavy metals effects on breast cancer progression. *Journal of Occupational Medicine and Toxicology*. 2017;12:32. Retrieved from: <https://occup-med.biomedcentral.com/articles/10.1186/s12995-017-0178-1>
13. Romaniuk A, Lyndin M, Moskalenko R, Gortinskaya O, Lyndina Y. The role of

heavy metal salts in pathological biomineralization of breast cancer tissue. *Advances in Clinical and Experimental Medicine*. 2016;25(5):907-910. doi: 10.17219/acem/34472

14. Romaniuk A, Lyndin M, Moskalenko R, Gladchenko O, Lyndina Y. Pathogenetic mechanisms of heavy metals effect on proapoptotic and proliferative potential

of breast cancer. *Medicine*. 2015;7(2):63–68. Retrieved from: <https://www.ncbi.nlm.nih.gov/pmc/articles/PMC4464767/> doi: 10.1556/1646.7.2015.2.4 PMID: 26120478

(received 12.05.2020, published online 29.06.2020)

(одержано 12.05.2020, опубліковано 29.06.2020)