

© 2025 by the author(s).

This work is licensed under Creative Commons Attribution 4.0 International License  
<https://creativecommons.org/licenses/by/4.0/>



**How to cite:** Lisovyi V, Kolupayev S, Andonieva N, Lisova M, Chernyak M, Gargin V. Methodology of processing medical images with assessment of crystallinity degree of renal stones. *East Ukr Med J.* 2025;13(2):434-441

**DOI:** [https://doi.org/10.21272/eumj.2025;13\(2\):434-441](https://doi.org/10.21272/eumj.2025;13(2):434-441)

## ABSTRACT

**Volodymyr Lisovyi**

<https://orcid.org/0000-0001-8149-1232>

Department of Urology, Nephrology and Andrology n.a. A.G. Podrez,, Kharkiv National Medical University, Kharkiv, Ukraine

**Sergiy Kolupayev**

<https://orcid.org/0000-0001-7128-4555>

Department of Urology, Nephrology and Andrology n.a. A.G. Podrez,, Kharkiv National Medical University, Kharkiv, Ukraine

**Nina Andonieva**

<https://orcid.org/0000-0002-8122-8263>

Department of Urology, Nephrology and Andrology n.a. A.G. Podrez,, Kharkiv National Medical University, Kharkiv, Ukraine

**Maria Lisova**

<https://orcid.org/0000-0003-0857-9646>

Department of Professionally Oriented Disciplines Kharkiv International Medical University, Kharkiv, Ukraine

**Mychaylo Chernyak**

<https://orcid.org/0000-0002-7425-659X>

Department of Public Health and Healthcare Management, Kharkiv National Medical University, Kharkiv, Ukraine

## METHODOLOGY OF PROCESSING MEDICAL IMAGES WITH ASSESSMENT OF CRYSTALLINITY DEGREE OF RENAL STONES

**Introduction.** Urolithiasis is one of the most common urological diseases. The modern approach to the treatment of this pathology involves the use of a wide range of minimally invasive surgical interventions, the main stage of which is the destruction of the stone with subsequent removal of its fragments. Preoperative diagnosis of physicochemical parameters of kidney stones is of great practical importance in the aspect of choosing a treatment method, especially in the case of planning extracorporeal shock wave lithotripsy.

**The aim** of the study was to determine the peculiarities of tomographic images of kidney stones with various structural features.

**Materials and methods.** The research consisted in the study of the microstructure of stones removed as a result of minimally invasive surgical interventions (extracorporeal shock wave, percutaneous and ureteroscopic lithotripsy) in 63 patients with urolithiasis, by the method of crystal-optical analysis on a polarizing microscope, with subsequent digital analysis of their tomographic images, according to using the ImageJ software package, with determination of the average pixel intensity (PI) in the gray scale range of 0–250.

**Results.** During the crystal-optical analysis, it was established that regardless of the mineral composition of the stone, the inorganic components that make up its composition can be in an amorphous or crystalline state. The structural types of kidney stones were determined based on the determination of the volume fraction of the crystalline phase (VFPC) in the structure of the urolith. When analyzing tomographic images, it was found that kidney stones belonging to different structural types were characterized by different average pixel intensity (PI). A positive correlation between VFPC and PI was established, as well as reliable differences in the PI indicator between groups of stones of the first and third degree of crystallinity, which

**Vitaliy Gargin**

<https://orcid.org/0000-0001-8194-4019>  
 Pathological Anatomy Department,  
 Kharkiv National Medical University;  
 Department of Professionally Oriented  
 Disciplines Kharkiv International  
 Medical University, Kharkiv, Ukraine

allows considering this indicator as a tomographic criterion of the degree of crystallinity of a kidney stone, the determination of which is expedient at the stage of choosing a lithotripsy method.

**Conclusions.** Detection of the structural state of renal stones during tomographic examination could be performed with the methodology of determining the pixel intensity index using ImageJ software. In particular, 3 groups of renal stones can be distinguished according to pixel intensity: grade 1 (84–124), grade 2 (125–165) and grade 3 (166–206). This indicator is determined by the volume ratio of the amorphous and crystalline phases of mineral compounds of kidney stones and should be taken into account when choosing the optimal lithotripsy method.

**Key words:** renal stone, morphology, crystallinity, medical image.

*Corresponding author: Gargin Vitaliy, Kharkiv National Medical University, Kharkiv, Ukraine*

*e-mail: [vitgarg@ukr.net](mailto:vitgarg@ukr.net)*

**РЕЗЮМЕ****Володимир Лісовий**

<https://orcid.org/0000-0001-8149-1232>  
 Кафедра урології, нефрології та  
 андрології ім. А.Г. Подреза  
 Харківського національного  
 медичного університету, Харків,  
 Україна

**Сергій Колупасв**

<https://orcid.org/0000-0001-7128-4555>  
 Кафедра урології, нефрології та  
 андрології ім. А.Г. Подреза  
 Харківського національного  
 медичного університету, Харків,  
 Україна

**Ніна Андон'єва**

<https://orcid.org/0000-0002-8122-8263>  
 Кафедра урології, нефрології та  
 андрології ім. А.Г. Подреза  
 Харківського національного  
 медичного університету, Харків,  
 Україна

**Марія Лісова**

<https://orcid.org/0000-0003-0857-9646>  
 Кафедра професійно-орієнтованих  
 дисциплін Харківського  
 міжнародного медичного  
 університету, Харків, Україна

**Михайло Черняк**

<https://orcid.org/0000-0002-7425-659X>  
 Кафедра громадського здоров'я та  
 управління охороною здоров'я  
 Харківського національного  
 медичного університету, Харків,  
 Україна

**МЕТОДИКА ОБРОБКИ МЕДИЧНИХ ЗОБРАЖЕНЬ З ОЦІНКОЮ СТУПЕНЯ КРИСТАЛІЧНОСТІ НИРКОВИХ КАМЕНІВ**

**Вступ.** Сечокам'яна хвороба є одним з найбільш поширених урологічних захворювань. Сучасний підхід до лікування даної патології передбачає використання широкого спектру малоінвазивних оперативних втручань, основним етапом яких є деструкція конкременту з послідуочим видаленням його фрагментів. Передопераційна діагностика фізико-хімічних параметрів ниркових каменів має важливе практичне значення в аспекті вибору методу лікування, особливо у разі планування екстракорпоральної ударно-хвильової літотрипсії.

**Мета** дослідження полягала у визначенні особливостей томографічних зображень ниркових каменів з різними структурними особливостями.

**Матеріали і методи.** Дослідження полягало у вивченні мікроструктури каменів, видалених в результаті проведення малоінвазивних оперативних втручань (екстракорпоральної ударно-хвильової, перкутанної та уретероскопічної літотрипсії) у 63 пацієнтів з сечокам'яною хворобою, методом кристалооптичного аналізу на поляризаційному мікроскопі, з послідуочим цифровим аналізом їх томографічних зображень, за допомогою програмного пакета ImageJ, з визначенням показника середньої інтенсивності пікселів (ІІ) у діапазоні сірої шкали 0–250.

При проведенні кристалооптичного аналізу було встановлено, що незалежно від мінерального складу каменю, неорганічні компоненти, які входять до його складу, можуть перебувати в аморфному або кристалічному стані. На підставі визначення об'ємної частки кристалічної фази (ОЧКФ) у структурі конкременту були визначені 3 структурні типи ниркових каменів. При аналізі томографічних зображень було виявлено, що ниркові камені, які належали до різних структурних типів характеризувалися різною величиною середньої інтенсивності пікселів (ІІ). Була встановлена позитивна кореляційна залежність між ОЧКФ та ІІ, що дозволяє розглядати даний показник як томографічний критерій ступеня кристалічності ниркового каменю, визначення якого є доцільним на етапі вибору методу літотрипсії.

**Віталій Гаргін**<https://orcid.org/0000-0001-8194-4019>

Кафедра патологічної анатомії  
Харківського національного  
медичного університету;  
Кафедра професійно-орієнтованих  
дисциплін Харківського  
міжнародного медичного  
університету, Харків, Україна

**Висновки.** При визначенні структурного стану ниркових каменів під час томографічного дослідження може бути використана методологія визначення показника інтенсивності пікселів за допомогою програмного забезпечення ImageJ. Зокрема можуть бути відокремлені 3 групи ниркових каменів відповідно до інтенсивності пікселів: 1 ступеню (84–124), 2 ступеню (125–165) та 3 ступеню (166–206). Даний показник залежить від об'ємного співвідношення аморфної та кристалічної фаз мінеральних сполук ниркового каміння та має бути врахованим при виборі оптимального методу літотрипсії.

**Ключові слова:** нирковий камінь, морфологія, кристалічність, медичне зображення.

**Автор, відповідальний за листування:** Гаргін Віталій Віталійович, Харківський національний медичний університет, Харків, Україна  
e-mail: [vitgarg@ukr.net](mailto:vitgarg@ukr.net)

**ABBREVIATIONS**

MSCT - multispiral computed tomography  
ESWL - extracorporeal shock wave lithotripsy  
USL - uteroscopic lithotripsy  
PNL - percutaneous nephrolithotripsy

VFCP - volume fraction of the crystalline phase  
HU - Hounsfield Units  
PI - pixel intensity  
WL - window level

**INTRODUCTION**

The last decade has characterized a significant increase in obtained medical images from different radiant (ultrasound, tomography, X-ray, and other) and microscopical (cytological, histological, immunohistochemical) method examinations that improve diagnostic measures and quality of treatment together with development of noninvasive technology [1–3]. Simultaneously that realized increasing burden for medical specialists of different fields with the necessity to have skills in image analysis, herewith results of the analysis should be objective with escaping human factor mistakes that perform conditions for more widespread involvement of computer vision and artificial intellect systems with using of commercial and non-commercial software [4, 5]. Such performance of image analysis allows to organize distance consultation that is crucial in pandemic time and time of war.

Urolithiasis is one of the most common diseases with a recurrent course [6–8]. Modern protocols for the treatment of this pathology involve the use of non-invasive and minimally invasive methods, the principle of which is the extra- or intracorporeal destruction of the stone with the subsequent elimination of its fragments, which include various types of lithotripsy: extracorporeal shock-wave, percutaneous and ureteroscopic [9, 10].

**The purpose of the work** consisted in the improvement of diagnostic quality of study of urolithiasis by detection of tomographic signs of kidney stones with different structural conditions.

**MATERIALS AND METHODS**

The paper studied the peculiarities of tomographic images of kidney stones of different structural types obtained as a result of minimally invasive surgical interventions for urolithiasis in 63 patients aged 20–73 years (average age 46.4±8.5 years). At the stage of preoperative diagnosis, multispiral computed tomography (MSCT) was performed on all patients on a Toshiba Aquilion 16 multispiral computer tomograph. Extracorporeal shock wave lithotripsy (ESWL) was used as a treatment method for the stone in 31 (49.2%) patients, in 17 (27%) patients uteroscopic lithotripsy (USL) was performed, 15 (23.8%) patients underwent percutaneous nephrolithotripsy (PNL). The obtained fragments of kidney stones were studied by the method of crystal-optical analysis on a polarizing microscope POLAM (Lomo), the structural state of the mineral components of the stone and the degree of its crystallinity were evaluated by calculating the volume fraction of the crystalline phase (VFCP) in its composition. A crystalline phase was present in all studied kidney stone samples; stones with a completely amorphous structure were absent. The renal stones were analyzed in the axial or coronal plane, which corresponded to the maximum linear size of the stone in the native phase of the tomographic study.

Tomographic images of kidney stones were analyzed using the Radiant DICOM Viewer program by a single radiologist. Hounsfield Units (HU) were used for measure of the X-ray density of stones, where 1000

HU corresponds to the density of air and 0 HU to the density of water. Digital analysis of the tomographic image of the stone was carried out using the ImageJ software package, based on the calculation of the average pixel intensity (PI) in the grey scale range 0–250 [11, 12]. For the purpose of standardization, the images were analyzed at an 8-fold magnification (Zoom = 800%), in the viewing mode with a window level (WL) corresponding to 700.

Statistical data processing was carried out using the Statistica 12 program (StatSoft, USA). Median (Me), first and third quartiles (Q1–Q3) were used as average sample characteristics. The presence of correlation was assessed using the Spearman method, the correlation coefficient is presented in the form of  $r$ . The significance of the differences was accepted at the level of statistical significance of  $p < 0.05$ .

The study was carried out in accordance with the principles of the Declaration of Helsinki and was approved by the ethics committee of "Regional Medical Clinical Center of Urology and Nephrology named after V.I. Shapoval". Patients were informed about the purpose, methods, and design of the study and signed an informed consent.

## RESULTS


During the crystal-optical analysis of urinary stone samples, it was established that regardless of the mineral composition of the stone, the inorganic components included in its composition are in an amorphous or crystalline state. Depending on the volume ratio of amorphous and crystalline phases, 3 structural types of kidney stones were determined. Structural type A: amorphous-crystalline structure, with a predominant content of an amorphous phase (VFCP < 50% by volume), microscopically represented by an amorphous component with single crystallization

centers and fine-crystalline inclusions. Structural type B: amorphous-crystalline structure, with a predominant content of the crystalline phase (VFCP > 50% by volume), mainly represented by a fine crystalline mass, among which there are formed grains of crystals with different degrees of transparency. Structural type C: there is no amorphous phase, the sample is completely represented by crystalline phases (VFCP = 100%vol), the main components of which are formed crystals in the form of grains with characteristic structural features, depending on the type of mineral.

During the visual evaluation of the tomographic images of stones of different structural types, a different degree of their color saturation was revealed. The color heterogeneity of urinary stones was clearly differentiated in viewing modes in which the WL value was in the range of 650–750. For quantitative analysis and objectification of color characteristics of images, the ImageJ program was used, which was developed by the National Institute of Health (USA) and is used for digital processing of medical images [13, 14].

In this study, when analyzing tomographic images of urinary stones using the ImageJ software, it was found that stones of different structural types were characterized by different values of the average pixel intensity (PI) (Fig. 1–3).

As the quantitative presence of the crystalline phase in the stone structure increased, an increase in the average intensity of pixels in its tomographic image was observed. When conducting a correlation analysis, a statistically significant positive relationship was found between the indicators of VFCP and PI ( $p < 0.05$ ;  $r = 0.51$ ), which allows us to consider the IP indicator as a tomographic criterion of the structural state of a kidney stone, which characterizes the degree of crystallinity of its mineral components.



**Fig. 1. Tomographic image of a kidney stone (structural type A): 800x magnification, WL=700 (a) and its corresponding ImageJ histogram (b)**

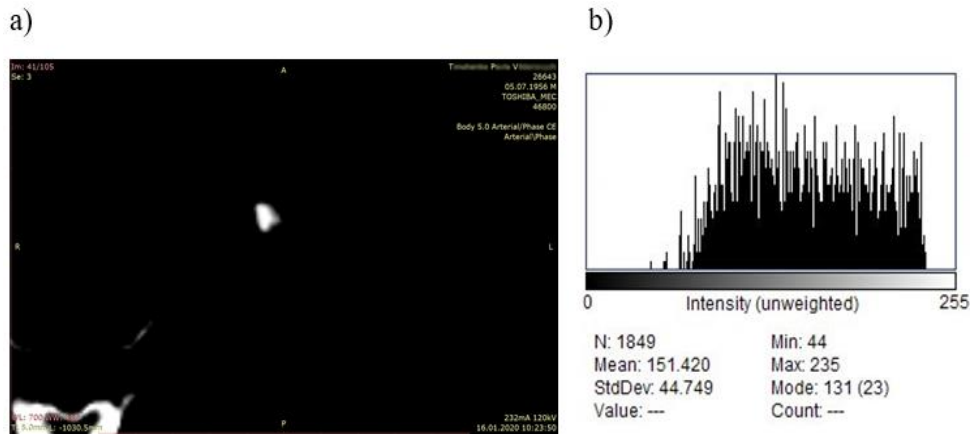


Fig. 2. Tomographic image of a kidney stone (structural type B): 800x magnification, WL=700 (a) and the corresponding ImageJ histogram (b)

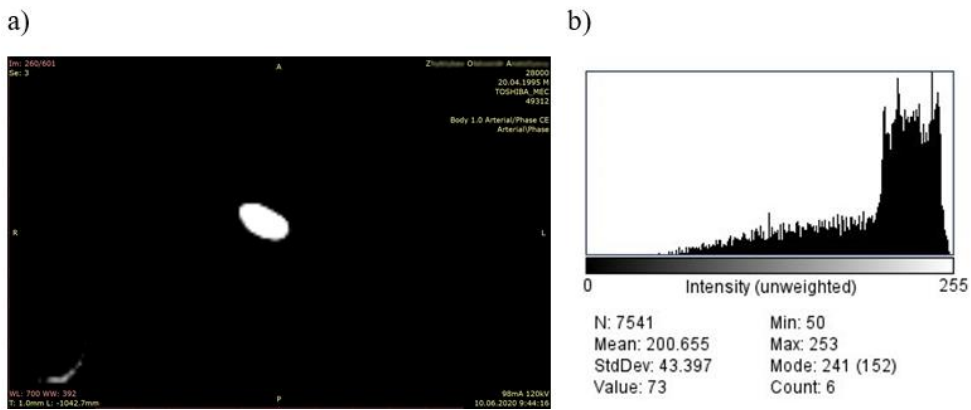


Fig. 3. Tomographic image of a kidney stone (structural type C): 800x magnification, WL=700 (a) and the corresponding ImageJ histogram (b)

Based on the results of this study, the minimum and maximum values of the average pixel intensity of urinary stones were 84 and 206, respectively. The proportional distribution of the values of this indicator within the range made it possible to distinguish 3 degrees of crystallinity of kidney stones (Table 1).

**Table 1. Distribution of degrees of crystallinity of kidney stones depending on the average pixel intensity of urinary stones**

Degree of crystallinity	1 degree	2 degree	3 degree
Pixel intensity	84–124	125–165	166–206

### DISCUSSION

The current trend in the treatment of urolithiasis is the use of various types of lithotripsy, among which in most patients with stone sizes less than 2 cm, ESWL is considered as the first-line method [15, 16]. Among the

factors that affect the results of treatment, the fragility of the stone is important, which depends on its compositional and structural features [17]. Despite the common belief that X-ray stone density (HU) is an indicator of susceptibility to lithotripsy, in practice, kidney stones with the same or similar HU values show significant variability in the structure and hardness of the material [18, 19].

The nature of stone fragmentation is determined by the type and structural state of the mineral components that make up its composition and is one of the factors affecting the results of treatment [20, 21]. It is possible to assess the structural and compositional features of kidney stones by laboratory analysis of their samples obtained as a result of the above-described treatment methods, however, in clinical practice, the determination of the stone's physicochemical properties at the stage of preoperative diagnosis is important. Modern literature describes methods of identifying the mineral components of kidney stones using dual-energy tomography [22], but diagnostic criteria for their

structural state have not been developed, which determines the relevance of this direction of scientific research.

Diagnostic measures are limited for investigation of organs of urinary systems and often require invasive manipulations for detection of morphological changes [23–25]. But it could be implemented with perfectibility of visualization, for example in our previous study, the relationship between the structural state of the stone and its X-ray density in Hounsfield units (HU) was not established [26] and the determination of the volume fraction of the crystalline phase by polarization microscopy was carried out using the method of quantitative analysis of microscopic images [27, 28]. Suggested methodology could be proposed in automatic

analysis of medical images to improve the quality of diagnostics when using digital medicine and artificial intelligence tools in vital systems.

### CONCLUSIONS

Detection of the structural state of renal stones during tomographic examination could be performed with the methodology of determining the pixel intensity index using ImageJ software. In particular, 3 groups of renal stones can be distinguished according to pixel intensity: grade 1 (84–124), grade 2 (125–165) and grade 3 (166–206). This indicator is determined by the volume ratio of the amorphous and crystalline phases of mineral compounds of kidney stones and should be considered when choosing the optimal lithotripsy method.

### PROSPECTS FOR FUTURE RESEARCH

The prospect of further research is to determine the possibility of using the proposed method in automatic analysis of medical images to improve the quality of diagnostics when using digital medicine and artificial intelligence tools.

### AUTHOR CONTRIBUTIONS

Conceptualization: L. V. and K. S.; methodology: G. V., L. M., A. N. and Ch. M.; formal analysis: K. M., L. M.; research A. N., Ch. M., K. S. and G. V.; data curation: Ch. M. and A. N.; writing – preparation of the original paper: L. V., K. S., L. M. and A. N.; writing – review and editing: L. V., K. S. and V. G.; visualization: A. N., Ch. M. and L. M.; guidance: L. V. All authors have read and agreed with the published version of the manuscript.

### FUNDING

The study was carried out within the framework of the research work of the Kharkiv National Medical University “Diagnosis and treatment of urological diseases in adults and children” (state registration number 0122U600028).

### CONFLICT OF INTEREST

The authors declare no conflict of interest.

### REFERENCES

- Ijaz A, Nabeel M, Masood U, et al. Towards using cough for respiratory disease diagnosis by leveraging Artificial Intelligence: A survey. *Informatics in Medicine Unlocked*. 2022; 29, art. no. 100832. <https://doi.org/10.1016/j.imu.2021.100832>
- Nechyporenko A, Frohme M, Strelchuk Y, Omelchenko V, Gargin V, Ishchenko L, Alekseeva V. Galvanic Skin Response and Photoplethysmography for Stress Recognition Using Machine Learning and Wearable Sensors. *Applied Sciences*. 2024; 14(24):11997. <https://doi.org/10.3390/app142411997>
- Behar JA, Bonnemains L, Shulgina V, Oster J, Ostras O, Lakhno I. Noninvasive fetal electrocardiography for the detection of fetal arrhythmias. *Prenat Diagn*. 2019;39(3):178-187. <https://doi.org/10.1002/pd.5412>
- Krivenko S, Krylova O, Bataeva E, Lukin V. Smart lossy compression of images based on distortion prediction. *Telecommunications and Radio Engineering (English translation of Elektrosvyaz and Radiotekhnika)*. 2018;77(17):1535-1554. <https://doi.org/10.1615/TelecomRadEng.v77.i17.40>
- Ripollés T, Martínez-Pérez MJ, Vizuete J, Miralles S, Delgado F, Pastor-Navarro T. Sonographic diagnosis of symptomatic ureteral calculi: usefulness of the twinkling artifact. *Abdom Imaging*. 2013;38(4):863-869. <https://doi.org/10.1007/s00261-012-9946-7>
- Sorokin I, Mamoulakis C, Miyazawa K, Rodgers A, Talati J, Lotan Y. Epidemiology of stone disease across the world. *World J Urol*. 2017;35(9):1301-1320. <https://doi.org/10.1007/s00345-017-2008-6>
- Alatab S, Pourmand G, El Howairis Mel F, et al. National Profiles of Urinary Calculi: a Comparison Between Developing and Developed Worlds. *Iran J Kidney Dis*. 2016;10(2):51-61.
- Kolupayev S, Lisovyi V, Andonievna N, Geletka O, Lisova M, Vitaliy G. Neurophysiological aspects of electrical pulse stimulation in patients with urolithiasis. *Pol Merkur Lekarski*. 2022;50(300):348-351.
- Al-Marhoon MS, Shareef O, Al-Habsi IS, Al Balushi AS, Mathew J, Venkiteswaran KP. Extracorporeal Shock-wave Lithotripsy Success Rate and Complications: Initial Experience at Sultan Qaboos

- University Hospital. *Oman Med J*. 2013;28(4):255-259. <https://doi.org/10.5001/omj.2013.72>
10. Turk C, Neisius A, Petrik A, Seitz C, Skolarikos A, Thomas K, Davis NF, Donaldson JF, Lombardo R, Grivas N, Ruhayel Y. *EAU Guidelines on Urolithiasis*. Edn. presented at the EAU Annual Congress Amsterdam 2020. ISBN 978-94-92671-07-3. <https://uroweb.org/guideline/urolithiasis>
  11. Seletchi ED, Dului OG. Image Processing and Data Analysis in Computed Tomography. *Romanian Journal of Physics*. 2007;72:764-774.
  12. Brookes SJ. Using ImageJ (Fiji) to Analyze and Present X-Ray CT Images of Enamel. *Methods Mol Biol*. 2019;1922:267-291. [https://doi.org/10.1007/978-1-4939-9012-2\\_26](https://doi.org/10.1007/978-1-4939-9012-2_26).
  13. Curvo LRV, Ferreira MW, Costa CS, Barbosa GRC, Uhry SA, Silveira US da, et al. Techniques using ImageJ for histomorphometric studies. *RSD [Internet]*. 2020 Nov. 11 ;9(11): e1459119586. Available from: <https://rsdjournal.org/index.php/rsd/article/view/9586>
  14. Schroeder AB, Dobson ETA, Rueden CT, Tomancak P, Jug F, Eliceiri KW. The ImageJ ecosystem: Open-source software for image visualization, processing, and analysis. *Protein Sci*. 2021;30(1):234-249. <https://doi.org/10.1002/pro.3993>
  15. Abedi AR, Razzaghi M, Montazeri S, Allameh F. The Trends of Urolithiasis Therapeutic Interventions over the Last 20 Years: A Bibliographic Study. *J Lasers Med Sci*. 2021 Apr 21;12:e14. <https://doi.org/10.34172/jlms.2021.14>.
  16. Lawler AC, Ghiraldi EM, Tong C, Friedlander JJ. Extracorporeal Shock Wave Therapy: Current Perspectives and Future Directions. *Curr Urol Rep*. 2017;18(4):25. <https://doi.org/10.1007/s11934-017-0672-0>
  17. Kijvikai K, de la Rosette JJ. Assessment of stone composition in the management of urinary stones. *Nat Rev Urol*. 2011;8(2):81-85. <https://doi.org/10.1038/nrurol.2010.209>
  18. Sherer BA, Chen L, Yang F, Ramaswamy K, Killilea DW, Hsi RS, et al. Heterogeneity in calcium nephrolithiasis: A materials perspective. *Journal of Materials Research*. 2017;32:2497–2509. <https://doi.org/10.1557/jmr.2017.153>
  19. Mehta A, Andrew Awuah W, et al. Telesurgery's potential role in improving surgical access in Africa. *Ann Med Surg (Lond)*. 2022 Aug 30;82:104511. <https://doi.org/10.1016/j.amsu.2022.104511>.
  20. Pittomvils G, Vandeursen H, Wevers M, Lafaut JP, De Ridder D, De Meester P, et al. The influence of internal stone structure upon the fracture behaviour of urinary calculi. *Ultrasound Med Biol*. 1994;20(8):803-10. [https://doi.org/10.1016/0301-5629\(94\)90037-x](https://doi.org/10.1016/0301-5629(94)90037-x).
  21. Myronov P, Bugaiov V, Holubnychy V, et al. Low-frequency ultrasound increase effectiveness of silver nanoparticles in a purulent wound model. *Biomed Eng Lett*. 2020 Oct 17;10(4):621-631. <https://doi.org/10.1007/s13534-020-00174-5>.
  22. Nestler T, Nestler K, Neisius A, Isbarn H, Netsch C, Waldeck S, Schmelz HU, Ruf C. Diagnostic accuracy of third-generation dual-source dual-energy CT: a prospective trial and protocol for clinical implementation. *World J Urol*. 2019 Apr;37(4):735-741. <https://doi.org/10.1007/s00345-018-2430-4>.
  23. Romaniuk A, Sikora V, Lyndin M, Smiyanov V, Sikora V, Lyndina Yu, Piddubnyi A, Gyravenko N, Korobchanska A. The features of morphological changes in the urinary bladder under combined effect of heavy metal salts. *Interv Med Appl Sci*. 2017;9(2):105–11. <https://doi.org/10.1556/1646.9.2017.2.09>.
  24. Romaniuk A, Sikora V, Lyndina Yu, Lyndin M, Hyriavenko N, Sikora V, Karpenko L, Piddubnyi A, Miroshnichenko M. Effect of heavy metals on the readaptive processes in the urinary bladder. *Bangladesh Journal of Medical Science*. 2019;18(1):100–6. <https://doi.org/10.3329/bjms.v18i1.39558>
  25. Sikora V, Lyndin M, Hyriavenko N, Moskalenko R, Lyndina Y, Sikora K, Chyzhma R, Diachenko O, Romaniuk A. Morphological peculiarities of parasitic (*Trichosomoides crassicauda*) infection in rat urinary bladder. *Mac Vet Rev*. 2021;44 (2):159-167. <https://doi.org/10.2478/macvetrev-2021-0019>.
  26. Kolupayev S, Lesovoy V, Bereznyak E, Andoniev N, Shchukin D. Structure Types of Kidney Stones and Their Susceptibility to Shock Wave Fragmentation. *Acta Inform Med*. 2021;29(1):26-31. <https://doi.org/10.5455/aim.2021.29.26-31>
  27. Romanjuk A, Lyndin M, Moskalenko R, Gortinskaya O, Lyndina Y. The Role of Heavy Metal Salts in Pathological Biomineralization of Breast Cancer Tissue. *Adv Clin Exp Med*. 2016 Sep-Oct;25(5):907-910. <https://doi.org/10.17219/acem/34472>.
  28. James J, Tanke HJ. *Biomedical Light Microscopy*. Springer, Netherlands: Springer; 1991. <https://doi.org/10.1007/978-94-011-3778-2>

Received 18.02.2025

Accepted 10.05.2025

## INFORMATION ABOUT THE AUTHORS

### Lisovyi Volodymyr Mykolaiovych

Doctor of Medical Sciences, Professor, Head of the department of urology, nephrology and andrology n.a. A.G. Podrez,, Kharkiv National Medical University, corresponding member of the National Academy of Medical Sciences of Ukraine, Kharkiv, Ukraine

ORCID: 0000-0001-8149-1232

E-mail: [vm.lisovyi@knmu.edu.ua](mailto:vm.lisovyi@knmu.edu.ua)

**Kolupayev Sergiy Mykhailovych**

Doctor of Medical Sciences, Associate Professor of the department of urology, nephrology and andrology n.a. A.G. Podrez,, Kharkiv National Medical University.

ORCID: 0000-0001-7128-4555

E-mail: [sm\\_kolupayev@ukr.net](mailto:sm_kolupayev@ukr.net)

**Andonievva Nina Mykhailivna**

Doctor of Medical Sciences, Associate Professor of the department of urology, nephrology and andrology n.a. A.G. Podrez,, Kharkiv National Medical University.

ORCID: 0000-0002-8122-8263

E-mail: [nm.andonievva@knmu.edu.ua](mailto:nm.andonievva@knmu.edu.ua)

**Lisova Maria Arshavyrivna**

Doctor of Medical Sciences, Professor of Department of Professionally Oriented Disciplines Kharkiv International Medical University, Kharkiv, Ukraine.

ORCID: 0000-0003-0857-9646

**Chernyak Mychaylo**

PhD, assistant of Department of public health and healthcare management, Kharkiv National Medical University

ORCID: 0000-0002-7425-659X.

e-mail: [mycherniak.4m20@knmu.edu.ua](mailto:mycherniak.4m20@knmu.edu.ua)

**Gargin Vitaliy Vitaliyovych**

Doctor of Medical Sciences, Professor of Pathological Anatomy Department, Kharkiv National Medical University, Professor of Department of Professionally Oriented Disciplines Kharkiv International Medical University, Kharkiv, Ukraine

ORCID: 0000-0001-8194-4019

E-mail: [vitgarg@ukr.net](mailto:vitgarg@ukr.net)