

## Abstract

**P. F. Myronov,**  
**V. I. Bugaiov,**  
**O. O. Tymakova,**  
**M. V. Pogorielov,**  
**A. S. Opanasyuk,**  
*Sumy State University*  
*2, Rymaskogo-Korsakova st., Sumy,*  
*Ukraine, 40007*

### CYTOLOGICAL EXAMINATION OF EXPERIMENTAL PURULENT WOUNDS IN THE TREATMENT OF SILVER NANOPARTICLES IN ULTRASOUND CAVITATION

The treatment of purulent wounds is an important problem of modern surgery. Antibiotic resistance of bacteria dramatically reduces the effectiveness of traditional methods of treatment. Previous studies have indicated that silver nanoparticles have good antibacterial activity and do not cause bacterial resistance. Low-frequency ultrasound improves the bactericidal properties of nanoparticles, as well as plays an important role in cleaning wounds from purulent-necrotic tissue and delivering nanoparticles to the site of infection. The combination of the properties of silver nanoparticles and low-frequency ultrasound requires careful investigation in the treatment of purulent wounds.

The purpose of the study was to substantiate the effectiveness of the treatment of purulent wounds with silver nanoparticles and low-frequency ultrasound by cytological examination.

**Materials and Methods.** This study was carried out on 60 laboratory rats, which were equally divided into 3 groups. In the first group, treatment was carried out by low-frequency ultrasound; in the second group, a solution of silver nanoparticles was used together with low-frequency ultrasound; in the third, control group, a 0.05% Chlorhexidine solution was used. Silver nanoparticles with a size of 10-60 nm were synthesized by the polyol method.

**Results.** The study showed that there were no statistically significant differences between the ultrasound, silver nanoparticles/ultrasound and Chlorhexidine groups on the first day. On the third day, a statistically significant increase in phagocytic neutrophilic leukocytes and fibroblasts was observed in the silver nanoparticles/ultrasound group compared with the first day. In comparison with the Chlorhexidine group, the number of monocytes (2.2 and 4.2 times) and macrophages (1.4 and 1.9 times) increased in the ultrasound and silver nanoparticles/ultrasound groups respectively, and the necrotic type of cytograms was not determined. On the seventh day, granulation tissue began to appear in the silver nanoparticles/ultrasound group, the percentage of leukocyte destruction decreased (by 4.5 times), microorganisms were almost not detected, regenerative types of cytograms appeared for the first time. The number of neutrophils in the control group exceeded the analogous parameter of the ultrasound group by 2.4 times and the silver

nanoparticles/ultrasound group by 3.8 times. The number of fibroblasts became significantly larger in the ultrasound (2.2 times) and the silver nanoparticles/ultrasound (2.3 times) groups, compared with the group where Chlorhexidine was used. On the tenth day, the number of fibroblasts and cells of the monocytic-macrophage series increased in the control group, which indicates later regenerative processes. On the tenth day, there was a complete epithelization of wounds in the silver nanoparticles/ultrasound group, while healing occurred on day 12 in the ultrasound group, and on day 21 in the control group.

**Conclusions.** The combined use of silver nanoparticles and low-frequency ultrasound significantly improves the cytological parameters of wound healing of purulent wounds and has clear advantages over the ultrasound monotherapy and the use of Chlorhexidine. The presented method reduces the treatment time and can be prospectively introduced into surgical practice.

**Key words:** silver nanoparticles, cytology, ultrasound, purulent wounds.

**Corresponding author:** [p.myronov@med.sumdu.edu.ua](mailto:p.myronov@med.sumdu.edu.ua)

#### Резюме

**П. Ф. Миронов,  
В. І. Бугайов,  
О. О. Тимакова,  
М. В. Погорєлов,  
А. С. Опанасюк,**  
*Сумський державний  
університет,  
вул. Римського-Корсакова, 2,  
м. Суми, Україна, 40007*

#### ЦИТОЛОГІЧНЕ ДОСЛІДЖЕННЯ ЕКСПЕРИМЕНТАЛЬНИХ ГНІЙНИХ РАН ПРИ ЛІКУВАННІ НАНОЧАСТИНКАМИ СРІБЛА В УМОВАХ УЛЬТРАЗВУКОВОЇ КАВІТАЦІЇ

Робота присвячена цитологічному дослідженню експериментальних гнійних ран при лікуванні низькочастотним ультразвуком та наночастинками срібла в умовах низькочастотного ультразвуку. Експеримент виконаний на 60 білих нелінійних лабораторних щурах, які були порівну поділені на 3 групи. В першій групі лікування здійснювалось хірургічним низькочастотним ультразвуковим апаратом УРСК 7Н–22. В другій групі обробку ран здійснювали апаратом УРСК 7Н–22 з 0,01 % розчином наночастинок срібла з наступним накладанням марлевої пов'язки, змоченої 0,02 % розчином наночастинок срібла. В третій, контрольній групі, лікування здійснювали 0,05 % розчином хлоргексидину.

Цитологічне дослідження виконувалось за методикою М. П. Покровської та М. С. Макарова у модифікації Д. М. Штейнберга. Оцінювалося відсоткове співвідношення клітин, ступінь деструкції нейтрофілів, наявність та розташування мікроорганізмів, типи цитогам, зміни клітинного складу в динаміці, терміни епітелізації.

Встановлено, що представлений спосіб поєднаного застосування наноструктурованого срібла та ультразвукової кавітації сприяє кращій елімінації мікробного обсіменіння, призводить до достовірного зменшення числа нейтрофільних лейкоцитів та лейкоцитів в стадії деструкції, збільшення відсотка фагоцитуючих лейкоцитів, фіброцитів, фібробластів, ендотеліоцитів та епітеліальних клітин, що свідчить про кращий антибактеріальний і протизапальний ефект та вказує на значно швидші процеси очищення та регенерації гнійних ран.

Комбіноване застосування наночастинок срібла та низькочастотного ультразвуку з урахуванням стадій ранового

процесу має значні переваги порівняно з монотерапією ультразвуком та традиційним лікуванням хлоргексидином і є перспективним для застосування в практиці гнійної хірургії.

**Keywords:** наночастинки срібла, цитологія, ультразвук, гнійні рани.

**Автор, відповідальний за листування:** [p.myronov@med.sumdu.edu.ua](mailto:p.myronov@med.sumdu.edu.ua)

## Introduction

Today the problem of purulent wound treatment remains one of the most urgent in surgery. Pyoinflammatory skin and soft tissues diseases occupy one of the leading places in the structure of nosocomial infections and complications [1]. The urgency of the problem increases due to the development of resistance of many strains of microorganisms to antibiotics and antiseptic agents [2]. Antibiotic resistance dramatically reduces the effectiveness of traditional methods of treatment, requires constant updating of the arsenal of drugs and the use of complex and expensive treatment methods [3]. As a consequence, surgeons often note purulent complications in the postoperative period (15-22%) and cases of generalized forms of infection (3-6%) [4, 5]. Unsatisfactory treatment results are gaining socio-economic importance.

To the present day, many of the issues of local treatment of purulent surgical infection remain open. At the same time, the requirements for primary surgical treatment of a purulent wound have increased, the effectiveness of which can be significantly increased due to modern methods of active influence on the nidus. The search of effective combinations of physical treatment methods and antiseptics that can release active substances into the wound for a long time, which will reduce the frequency of dressings and accelerate the healing processes, is being carried out [6]. One such antiseptics is silver nanoparticles (SNP), which are able to release ions and maintain an antibacterial effect for a long time [7].

Silver, as an antibacterial agent, has been used since ancient times [8]. However, over the past few decades, great interest has been drawn to the nanosilver, the structure of which reveals significantly new physical and chemical properties and functionality due to its nanosize. SNP exhibit a strong antibacterial activity against a wide range of microorganisms, fungi and viruses [9].

Resistance of bacteria to silver does not occur at all or occurs in very rare cases [10].

According to previous studies [11], the antibacterial properties of SNP are enhanced under the influence of low-frequency ultrasound (US) due to reduction of their agglomeration. In addition, US is also able to independently carry out a destructive effect on microorganisms and has a very important effect of phonophoresis, due to which the delivery of active substances into the thickness of the body tissues occurs [12]. This is especially important in the treatment of abscesses, phlegmon, postoperative complications, when it is necessary to ensure the availability of the drug in hard-to-reach places. The cavitation destructive effect of US helps to cleanse wounds from purulent necrotic tissues and, due to its low traumatization, does not cause damage to viable tissues [13].

Considering the above mentioned, the combination of the properties of SNP and low-frequency US is pathogenetically justified and requires careful study in the treatment of purulent soft tissue diseases. An important condition for improving the treatment effectiveness is to understand the cellular composition of wound exudate, which reflects the successive stages of healing.

According to K. Yao, L. Bae and W. Yew [14], when choosing a treatment method, it is necessary to take into account the phases of the wound process (inflammation, regeneration, scarring and epithelialization) in order to purposefully influence certain means. The proposed new method of treatment of purulent wounds allows to accelerate the healing process due to the targeted mechanical and antibacterial effects of US with SNP in the first phase and antiseptic wound treatment with SNP in the first, second and third phases of the wound process.

**Purpose:** to conduct a comparative cytological study of imprint smears of experimental purulent wounds in the treatment of low-frequency ultrasound, silver nanoparticles under ultrasonic cavitation in comparison with chlorhexidine.

### Materials and study methods.

The study of the peculiarities of the cytological pattern of skin regeneration was carried out on 60 white nonlinear laboratory rats in compliance with the "European Convention on the protection of vertebrates, used in experiments and other scientific purposes" (Strasbourg, 2005) and the "General ethical principles of animal experiments" approved by the Fifth National Congress on Bioethics (Kyiv, 2013). A model of a purulent wound was created by abscess formation: the wound defect was applied in the interscapular area with subsequent filing of a gauze swab moistened with a mixture of microorganisms *S. aureus*, *E. coli* and *P. aeruginosa* for three days. The experimental animals were equally divided into 3 groups: two main and one control.

In the first (20 rats) main group ("US"), the treatment of wounds was carried out by low-frequency ultrasound in saline solution with the help of a surgical ultrasound apparatus for the rehabilitation of biological objects URSK 7N-22 with a resonant frequency of 26.5 kHz, followed by the imposition of a sterile gauze bandage.

In the second (20 rats) main group ("SNP+US") treatment of wounds was carried out by low-frequency US (URSK 7N-22) with 0.01% SNP solution followed by the imposition (until complete healing) of gauze bandage moistened with 0.02% SNP solution, size 25-60 nm, synthesized by the polar method in an ethylene glycol solution (p.a. > 99.9%) using polyvinylpyrrolidone (K25) [11].

Treatment with low-frequency US in the main groups was carried out only in the first phase of the wound process. The duration of US treatment depended on the area of the wound defect and averaged 1 min/1 cm<sup>2</sup>.

In the third (20 rats), control ("Chlorhexidine") group after evacuation of purulent necrotic masses, wound treatment was carried out with 0.05 % chlorhexidine solution (registration certificate No. UA/5492/01/01, the validity period is unlimited from 19.05.2017) followed by the imposition of a sterile bandage.

Cytological examination was carried out by the M.P. Pokrovskaya and M.S. Makarov method in D.M. Steinberg's modification. Imprint smears from each experimental animal were made on the 1st, 3rd, 7th, 10th, 14th day of the experiment, dried, fixed for 5 minutes in methyl alcohol and

painted according to Romanovsky-Gimza. The cytograms were examined under a Nikon E 100 microscope. The cellular composition of imprint smears was represented by the following types of cells: neutrophils, lymphocytes, monocytes, polyblasts, fibroblasts, endotheliocytes, etc. The percentage of cells, the degree of destruction of neutrophils, the location of microorganisms (intra- and extracellularly), the types of cytograms, changes in cell composition in the dynamics, the timing of epithelization were evaluated. The cells were counted in 12-15 fields of vision with determination of an arithmetic average.

The results were processed on a personal computer using the programs "Microsoft Excel" and "Statistica 6.0". Statistical processing of the results was carried out by the method of variational statistics using the Student's criterion. The difference in values was considered significant at  $p \leq 0.05$ .

### Study results and discussion.

On the 1st day of observation, no statistically significant differences in the cellular composition of imprint smears were found. Necrotic and degenerative inflammatory types of cytograms were observed in all groups (Diagr. 1). Detritus, erythrocytes (many in the state of hemolysis), single eosinophils and a large number of neutrophils with gram-positive and gram-negative microflora, which was located extracellularly, were prevalent on the smears. Macrophages, fibroblastic cells and epithelium were absent. Only a small number of neutrophils were intact, the greater part is represented by various signs of dystrophic changes in the nucleus (pycnosis, lysis, rexis) and in the cytoplasm (vacuolation, fragmentation, intracellular oedema).

On the 3rd day (Table 1) neutrophilic leukocytes, as before, were predominant in the cellular composition of all groups, but the number of unchanged neutrophils and lymphocytes slightly increased. Starting from the third day in all groups the transformation of monocytes into macrophages mainly with incomplete phagocytosis can be observed. There was a statistically significant ( $p \leq 0.05$ ) increase in phagocytic neutrophil leukocytes and fibroblasts in the group of SNP+US compared to the first day. No similar changes were observed in the control group.

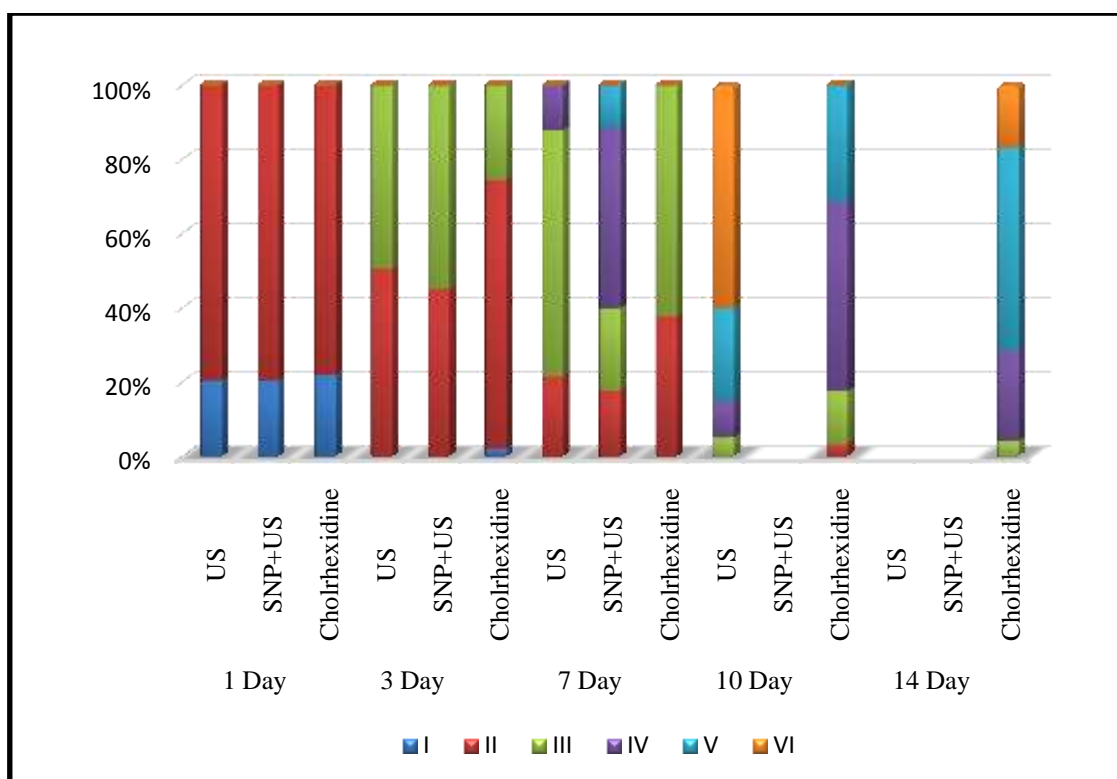


Diagram 1 – Types of cytograms of the studied groups

Note: Type I - necrotic, II - degenerative-inflammatory, III - inflammatory, IV - inflammatory-regenerative, V - regenerative-inflammatory, VI - regenerative.

Table 1 – Indicators of the cellular composition of the experimental and control groups on the 3rd day of observation, M ± m (n = 20)

Cytogram elements	Groups		
	US	SNP+US	Chlorhexidine
Number of leucocytes per field of vision	80.2±0.7*#	74.7±1.3*#	88.5±0.21
Destruction of leukocytes, %	72.6±0.32*#	67.4±0.75*#x	82.5±0.48*
Neutrophils, %	80.4±0.03*#	72.5±0.6*#x	86.7±0.1*
Lymphocytes, %	3.7±0.02#	4.5±0.2*#	2.5±0.3
Monocytes, %	1.3±0.07#	2.5±0.05*#	0.6±0.4
Macrophages, %	4.2±0.4*#	5.8±0.3*#	3.1±0.06*
Polyblasts, %	8.3±0.6*#	10.1±0.4*#	6.8±0.2*
Fibroblasts, %	1.7±0.4*#	2.8±0.2*#	0.3±0.1
Endotheliocytes, %	0.4±0.3*#	1.8±0.5*#x	0
Epithelium	-	single cells	-

Notes:

\* – the difference is likely compared to 1 day within one group (p ≤ 0.05);

# – the difference is likely compared to the "Chlorhexidine" group on the 3rd day (p ≤ 0.05);

x – the difference is likely compared to the "US" group on the 3rd day (p ≤ 0.05).

The number of monocytes (2.2 times in the US group; 4.2 times in the SNPS + US group) and macrophages (1.4 times in the US group; 1.9 times in the SNPS + US group) significantly (p ≤ 0.05)

increased compared with the control, which indicates a positive dynamics of the wound process. The percentage of neutrophils in the SNP+US group is significantly (p ≤ 0.05) less than in the US

group, and the percentage of endotheliocytes is significantly ( $p \leq 0.05$ ) is higher, indicating a faster process of wound cleaning and better regeneration processes in the SNP + US group. In contrast to the main groups with degenerative-inflammatory and imflammatory type (Diagr. 1), in the control group the necrotic type of cytogram was still preserved (2.15%). The number of bacteria in the main groups decreased significantly.

On the 7th day (Table 2) incomplete phagocytosis, single myelocytes, macrophages, polyblasts and unchanged erythrocytes prevailed in the control group of observation, a large number of polymorphonuclear leukocytes in the 3rd group indicated the activity of the protective reaction of the organism in the fight against infection. In the main groups, cellular detritus was not observed, isolated microorganisms were observed in some places, in the "US" group the granulation tissue formation signs began to appear: fibroblasts and histiocytes. In the main groups compared to the 3rd day the percentage of destruction of leukocytes (3.6-4.5 times) and neutrophilic leukocytes (3.4-4.7 times) significantly ( $p \leq 0.05$ ) decreased. The number of fibroblasts significantly ( $p \leq 0.05$ ) increased in all groups, indicating an active the process of connective tissue synthesis.

Macrophages were represented by large cells ranging in size from 16 to 24 microns with purple nuclei with compactly located chromatin; cytoplasm is weakly basophilic, with pronounced vacuolation. Fibroblasts are represented by oval, polygonal shape cells 20-28 microns in size. The nucleus usually had the shape of a cell with one or two well-defined nucleoli and a pulverized chromatin. Lymphocytes are round cells, 7-8 microns in size, with purple nuclei.

When comparing groups among themselves (Table 2), the number of neutrophils in the control group significantly ( $p \leq 0.05$ ) exceeded the values of the "US" group by 2.5 times, "SNP + US" group by 3.8 times. The number of fibroblasts in the main groups exceeded (2.2–2.3 times) the same value in the control group ( $p \leq 0.05$ ), which indicates the weakening of the acute inflammatory reaction and its transition to the regeneration phase with the formation of granulation tissue. Black SNP conglomerates are clearly visible on the cytograms, where SNP was used. The number of lymphocytes in the control group is less (1.2 times compared to the US group; 1.5 times compared to the SNP + US group), which indicates the oppression of specific immunity during reparative processes in wounds.

**Table 2 – Indicators of the cellular composition of the experimental and control groups on the 7rd day of observation,  $M \pm m$  (n = 20)**

Cytogram elements	Groups		
	US	SNP+US	Chlorhexidine
Number of leucocytes per field of vision	23.2±0.6* <sup>#</sup>	21.2±1.5* <sup>#</sup>	45.5±0.08*
Destruction of leukocytes, %	20±0.41* <sup>#</sup>	15±0.21* <sup>#x</sup>	42±0.32*
Neutrophils, %	23.8±0.15* <sup>#</sup>	15.5±0.05* <sup>#x</sup>	59.3±0.12*
Lymphocytes, %	3.6±0.03 <sup>#</sup>	4.3±0.18* <sup>#</sup>	2.9±0.21
Monocytes, %	1.4±0.22	2.4±0.11* <sup>#</sup>	0.8±0.09
Macrophages, %	24.3±0.14* <sup>#</sup>	26.7±0.21* <sup>#</sup>	11.1±0.08*
Polyblasts, %	21.7±0.17* <sup>#</sup>	22.2±0.4* <sup>#</sup>	14.7±0.16*
Fibroblasts, %	22.8±0.08* <sup>#</sup>	24.7±0.22* <sup>#</sup>	10.6±0.24*
Endotheliocytes, %	2.4±0.25* <sup>#</sup>	4.2±0.32* <sup>#x</sup>	0.6±0.16
Epithelium	cell groups	cell layers	single cells

Notes:

\* – the difference is likely compared to 3 day within one group ( $p \leq 0.05$ );

<sup>#</sup> – the difference is likely compared to the "Chlorhexidine" group on the 7th day ( $p \leq 0.05$ );

<sup>x</sup> – the difference is likely compared to the "US" group on the 7th day ( $p \leq 0.05$ ).

Regenerative types of cytograms were already observed in the main groups (Diagr. 1). In the second study group layers of epithelial cells with basophilic cytoplasm (in contrast to the US and

control groups) appeared, indicating a rapid transition of the healing process to the epithelization phase and reorganization of the scar. A significant number of degenerative-altered forms

of neutrophils were still present in imprint smears of the control group, which indicated a later degenerative-inflammatory stage of the process (type II cytogram) compared with the results, obtained in the main groups.

On the 10th day (Table 3) in the group "SNP+US" a complete epithelization of the wound

was observed. There was an increase in the number of fibroblasts in cytosmears with the use of the standard therapy, which indicates a later onset of regenerative processes in wounds compared to the US group. In the control group, a small number of lymphocytes remained almost unchanged, indicating weak specific immunological reactions.

**Table 3 – Indicators of the cellular composition of the experimental and control groups on the 10th day of observation,  $M \pm m$  (n = 20)**

Cytogram elements	Groups	
	US	Chlorhexidine
Number of leucocytes per field of vision	15.3±0.5* <sup>#</sup>	36.9±0.42*
Destruction of leukocytes, %	6.1±0.11* <sup>#</sup>	30.1±0.5*
Neutrophils, %	16.8±0.22* <sup>#</sup>	41.5±0.6*
Lymphocytes, %	3.2±0.02	2.7±0.11
Monocytes, %	1.6±0.22	2.5±0.21*
Macrophages, %	19.5±0.14* <sup>#</sup>	17.7±0.51*
Polyblasts, %	23.7±0.17* <sup>#</sup>	17.6±0.31*
Fibroblasts, %	29.9±0.08* <sup>#</sup>	16.4±0.42*
Endotheliocytes, %	5.3±0.25* <sup>#</sup>	1.6±0.16
Epithelium	cell layers	single cells

Notes:

\* – the difference is likely compared to 7 day within one group ( $p \leq 0.05$ );

<sup>#</sup> – the difference is likely compared to the "Chlorhexidine" group on the 10th day ( $p \leq 0.05$ )

In the "US" group were observed significant changes in the structure of the cellular composition of cytograms, namely: a significant ( $p \leq 0.05$ ) decrease in the total number of leukocytes, destroyed leukocytes, neutrophils and macrophages on the background of a significant ( $p \leq 0.05$ ) increase in the number of polyblasts, fibroblasts and endotheliocytes, which significantly differed from the values of the "Chlorhexidine" group. In the control group, a late increase in the proportion of monocyte-macrophage cells indicated adequate wound cleansing and was conditioned by complete rejection of necrotic tissues, in contrast to the "US" group, where a decrease in the number of macrophages indicates the completion of the infectious and inflammatory process.

In the "US" group, a small amount of microflora was located intracellularly, while phagocytosis proceeded in a complete manner, at the same time the process of marginal epithelization with basal epithelial cell layers was recorded. On most of the cytograms of the

"US" group, the regenerative type was observed, while in the chlorhexidine group the degenerative-inflammatory type (Diagr. 1) with single epithelial cells was still detected.

On the 12th day in the "US" group a complete epithelization of the wound was observed. On the 14th day in the control group (Table 3) a non-significant decrease in the total number of leukocytes was observed, while a large number of neutrophils was still in the stage of degeneration and destruction, there were signs of progressive phagocytic activity. A significant ( $p \leq 0.05$ ) increase in the percentage of fibroblasts and endotheliocytes indicated the presence of regenerative processes. Microflora was visualized in a state of incomplete and complete phagocytosis, in some cases microorganisms were isolated among the fragments of neutrophils. Regenerative-inflammatory and inflammatory types of cytograms were prevalent (Diagr. 1). Further cytological observation (14-21 days) indicated a positive dynamics of reparative processes.

**Table 4 – Indicators of the cellular composition of the experimental and control groups on the 14th day of observation, M ± m (n = 20)**

Cytogram elements	Group
	Chlorhexidine
Number of leucocytes per field of vision	30.2±0.35*
Destruction of leukocytes, %	18.4±0.28*
Neutrophils, %	29.6±0.22*
Lymphocytes, %	3.1±0.18
Monocytes, %	1.3±0.1*
Macrophages, %	20.4±0.12*
Polyblasts, %	19.7±0.11*
Fibroblasts, %	19.1±0.21*
Endotheliocytes, %	6.8±0.18*
Epithelium	Cell groups

Notes:

\* – the difference is likely compared to the 10th day ( $p \leq 0.05$ )

The obtained results of cytological research indicate faster wound healing processes when using low-frequency US, and, especially, with the combined US and SNP use. Faster transitions from one type of cytogram to another were observed in the "US" and "SNP+US" groups. Compared with the control group, the use of US allowed to reduce the duration of treatment by 1.75 times, and US together with SNP by 2.1 times.

It is known that one of the factors that complicates the course of the wound process is the presence of pathogenic microflora. In the main groups there was a significant decrease in microbial contamination of wounds starting from the third day. Hayashi D. [15] thinks that pronounced bactericidal effect of US is associated with the destruction of the bacterial cell membrane by the cavitation wave and the formation of chemical compounds that cause a destructive action on microorganisms. As a confirmation of this, on the 7th day of observation in the "US" group microorganisms were determined only in the state of phagocytosis, and in the "SNP+US" group were absent at all, while in the control group a significant number of them was still observed. The absence of bacteria in the "SNP+US" group can also be explained by additional SNP action. According to the study, conducted by Tashi T. et al. [7], this can be explained by the fact that SNP release ions for a long period of time and maintain a sustainable anti-microbial effect. Park H. J. et al. [16] believe that the bactericidal effect is created due to the interaction of SNP with the cell wall of

peptidoglycans, bacterial (cytoplasmic) DNA, as well as with enzymes involved in vital cellular processes, for example, the electron transport chain.

Reduction of inflammation indicator cells in the main groups is associated with silver-induced neutrophil apoptosis and decreased matrix metalloproteinase activity [17]. Prabhu S. et al. [18] establish the ability of SNP to reduce the activity of proinflammatory mediators, namely, the reduction of  $\gamma$ -interferon and TNF- $\alpha$  levels involved in the inflammatory process.

The cavitation effect of US also plays a great role in cleaning wounds from purulent necrotic tissues, stimulates the release of chemotactic factors and lysosomal enzymes, increases the proteolytic activity of exudate [14]. For example, on the 7th day in the control group there were still remains of purulent necrotic tissues, degenerative-altered leukocytes and degenerative-inflammatory types of cytograms, while in the groups, where US was used, granulation tissue without cell detritus prevailed in the cavities of wounds.

Tian J. et al. [19] proved that SNP play a positive role in the formation of fibrous tissue and post-traumatic scarring, and therefore in rapid healing, which is also confirmed by our studies with the only difference that the healing occurred by secondary tension. V.R. Driver believes [20] that US also stimulates connective tissue synthesis: activates the biosynthetic function of fibroblasts, optimizes the processes of fibrogenesis, promotes faster maturation of granulation tissue and its fibrous transformation. Starting from the third day,

the number of fibroblasts in the groups, where US was used, significantly exceeded the same value in the control group. However, the processes of wound cleaning, granulation formation and epithelization proceeded faster in the "SNP+US" group, which is probably due to the complementary action of SNP and US.

### Conclusions

1. In contrast to the control group, the cytological picture of imprint smears in the "US" group confirms the probability of neutralization of bacterial pathogens, the early transition of the inflammatory phase to the proliferative one, the faster course of the wound process and shorter treatment times.

2. Compared to chlorhexidine and US monotherapy, combined SNP and US use taking into account the phases of wound healing leads to a significant decrease in the number of neutrophils and white blood cells in the stage of decomposition,

It should be noted that SNP have low systemic toxicity [21]: During the whole study period there was not a single lethal case or manifestations of the so-called argyria among the animals in the main groups.

the percent of phagocytotic leukocytes, fibrocytes, fibroblasts and epithelial cells, suggesting a more rapid transition to the phase of regenerative changes. The cytological composition of the imprint smears indicated a decrease in inflammation, acceleration of the appearance of granulation tissue and faster epithelization of the wound defect.

3. Better cytological indicators of wound surfaces in the application of SNP in the conditions of low-frequency US allow us to refer this method of treatment to promising areas of purulent surgery.

### Acknowledgements

The work is carried out as a part of the dissertation research of P. F. Mironov "Treatment of purulent surgical infection by silver nanoparticles in the conditions of ultrasonic cavitation".

### Conflict of interest

The authors declare no conflict of interest.

### Information about the authors

Миронов Петро Федорович, аспірант кафедри хірургії та онкології МІ СумДУ, вул. Римського-Корсакова, 2, Суми, Україна, 40007;

Бугайов Володимир Іванович, к.м.н., доц. кафедри хірургії та онкології МІ СумДУ, вул. Римського-Корсакова, 2, Суми, Україна, 40007;

Тимакова Олена Олександрівна, викладач кафедри морфології МІ СумДУ, вул. Римського-Корсакова, 2, Суми, Україна, 40007;

Погорелов Максим Володимирович, д.м.н., проф. кафедри громадського здоров'я, заступник директора з наукової роботи МІ СумДУ, вул. Римського-Корсакова, 2, Суми, Україна, 40007;

Опанасюк Анатолій Сергійович, д.ф.-м.н., проф., завідувач кафедри електроніки і комп'ютерної техніки, СумДУ, вул. Римського-Корсакова, 2, Суми, Україна, 40007

### References

1. Bystrov SA, Bezborodov AI, Katorkin SE. Treatment of purulent wounds with wound dressing on a foamy basis with Hydrofiber technology. *Khirurgiia (Mosk)*. 2017;(7):49-53.
2. Pulcini C. Antibiotic stewardship: a European perspective. *FEMS microbiology letters*. 2017;364(23). doi:10.1093/femsle/fnx230
3. Avendano L. Antimicrobial resistance. Some aspects of a big problem. *Anales de la Real Academia Nacional de Farmacia*. 2017;4:380-391.
4. Gurusamy KS, Koti R, Wilson P, Davidson BR. Antibiotic prophylaxis for the prevention of methicillin-resistant *Staphylococcus aureus* (MRSA) related complications in surgical patients. *Cochrane Database Syst Rev*. 2013;19(8):CD010268. doi: 10.1002/14651858.CD010268.pub2
5. Hyun IK, Park PJ, Park D, Choi SB, Han HJ, Song TJ, Jung CW, Kim WB. Methicillin-

- resistant *Staphylococcus aureus* screening is important for surgeons. *Ann Hepatobiliary Pancreat Surg.* 2019;23(3):265-273. doi: 10.14701/ahbps.2019.23.3.265
6. Cheng YS, Williamson PR, Zheng W. Improving therapy of severe infections through drug repurposing of synergistic combinations. *Current Opinion in Pharmacology.* 2019;48:92-98.
  7. Tashi T, Vishal GN, Mbuya VB. Silver nanoparticles: Synthesis, mechanism of antimicrobial action, characterization, medical applications, and toxicity effects. *Journal of Chemical and Pharmaceutical Research.* 2016;8(2):526-537.
  8. Whitehouse MW. Silver pharmacology: Past, present and questions for the future. *Progress in Drug Research.* 2015;70:237-273.
  9. Franci G, Falanga A, Galdiero S, Palomba L, Rai M, Morelli G, Galdiero M. Silver nanoparticles as potential antibacterial agents. *Molecules.* 2015;20(5):8856-8874.
  10. RubenMorones-Ramirez J, Winkler JA, Spina CS, Collins JJ. Silver enhances antibiotic activity against gram-negative bacteria. *Science Translational Medicine.* 2013;5(19):190ra81.
  11. Holubnycha V, Myronov P, Bugaiov V, Opanasyuk A, Dobrozhan O, Yanovska A, Pogorielov M, Kalinkevich O. Effect of ultrasound treatment on chitosan-silver nanoparticles antimicrobial activity. *Proceedings of the 2018 IEEE 8th International Conference on Nanomaterials: Applications and Properties, NAP 2018, Zatoka, 2018*, pp. 04NNLS09-1-04NNLS09-4.
  12. Cardoso LCP, Pinto NB, Nobre MEP, Silva MR, Pires GM, Lopes MJP, Viana GSB, Rodrigues LMR. Anti-inflammatory and antinociceptive effects of phonophoresis in animal models: a randomized experimental study. *Braz J Med Biol Res.* 2019;52(2):e7773. doi: 10.1590/1414-431X20187773
  13. Chekmareva IA, Blatun LA, Paskhalova YS, Mitish VA, Paklina OV, Terekhova RP, Sepeda P, Magomedova SD, Ushakov AA, Sokov SL Morphological justification of the effectiveness of ultrasonic cavitation with 0.2 % Lavasept solution. *Khirurgiia (Mosk).* 2019;(7):63-70. doi: 10.17116/hirurgia201907163
  14. Yao K, Bae L, Yew WP. Post-operative wound management. *Aust Fam Physician.* 2013;42(12):867-70.
  15. Hayashi D, Kawakami K, Ito K, Ishii K, Tanno H, Imai Y, Kanno E, Maruyama R, Shimokawa H, Tachi M. Low-energy extracorporeal shock wave therapy enhances skin wound healing in diabetic mice: a critical role of endothelial nitric oxide synthase. *Wound Repair Regen.* 2012;20(6):887-95.
  16. Park HJ, Kim JY, Kim J. Silver-ion-mediated reactive oxygen species generation affecting bactericidal activity. *Water Res.* 2009;43(4):1027-1032.
  17. Thirumurugan G, Veni VS, Ramachandran S, Rao JV, Dhanaraju MD. Superior wound healing effect of topically delivered silver nanoparticle formulation using eco-friendly potato plant pathogenic fungus: synthesis and characterization. *J Biomed Nanotechnol.* 2011; 7(5): 659-66. PMID: 22195483
  18. Prabhu S, Poulouse E. Silver nanoparticles: mechanism of antimicrobial action, synthesis, medical applications, and toxicity effects. *International Nano Letters.* 2012; 2(32): 32-41.
  19. Tian J, Wong KK, Ho CM, Lok CN, Yu WY, Che CM, et al. Topical delivery of silver nanoparticles promotes wound healing. *Chem Med Chem.* 2007;2(1):129-36. PMID: 17075952. DOI:10.1002/cmdc.200600171
  20. Driver VR, Yao M, Miller CJ. Noncontact low frequency ultrasound therapy in the treatment of chronic wounds: a meta-analysis. *Wound Repair. Regen.* 2011;19(4):475-480.
  21. Chang BM, Pan L, Lin HH, Chang HC. Nanodiamond-supported silver nanoparticles as potent and safe antibacterial agents. *Sci Rep.* 2019;9(1):13164. doi: 10.1038/s41598-019-49675-z

(received 13.08.2019, published online 29.12.2019)

(одержано 13.08.2019, опубліковано 29.12.2019)